

Live Pregnancy in Non Communicating Horn of Unicornuate Uterus with Placenta Percreta: A Case Report and Review

DR. MINAKSHI ROHILLA¹, DR. PARUL ARORA^{1,*}, DR.RASHMI BAGGA¹, DR VANITA JAIN¹, DR GRV PRASAD¹

¹DEPARTMENT OF OBSTETRICS AND GYNAECOLOGY, POST GRADUATE INSTITUTE OF MEDICAL EDUCATION AND RESEARCH, NEHRU HOSPITAL, CHANDIGARH-160012

Abstract:

Objective:

Mullerian anomalies of the female genital tract are rare and unicornuate uterus is one such variant: it may present with a rudimentary horn with or without a communication. Pregnancy is rare in a non communicating horn and majority of them end up in rupture during first trimester. The ones which progress to fetal viability are around 10 % and may end up in catastrophic hemorrhage with fetal loss at any time.

Case report:

We hereby report a rare case of unruptured rudimentary horn pregnancy associated with placenta accreta and delivery of a live born fetus at 34 weeks period of gestation. Around ten cases of such an association have been reported in the past.

Conclusion:

Diagnosis of pregnancy in a non communicating horn of a unicornuate uterus is challenging especially at term. High index of suspicion and timely delivery of a live fetus has major role in achieving best maternal and neonatal outcome.

Corresponding author : DR. PARUL ARORA , RESEARCH OFFICER, DEPARTMENT OF OBSTETRICS AND GYNAECOLOGY, PGIMER, NEHRU HOSPITAL, CHANDIGARH- 160012, PH: +919914120666 +917087009354
Fax: 91-172-2744401, Email: drparul20arora@gmail.com

Key Words: Mullerian, Placenta accreta, Rudimentary horn, Unicornuate

Received: Sep 26,2017

Accepted: Oct 23,2017

Published: Oct 25,2017

Introduction:

Congenital anomalies of the female genital tract arise from defective fusion of the Mullerian ducts. Unicornuate uterus is one such anomaly which results from unilateral hypoplasia of the Mullerian duct and presents with a rudimentary horn with or without a functioning endometrium.

Rudimentary horn pregnancies are a rare occurrence with an incidence ranging from 1:100000 to 1:140000 pregnancies [1]. With advances in imaging, such pregnancies can often be diagnosed in early trimester but with advancing gestation, the diagnosis becomes more challenging and is often missed.

Such pregnancies often end up in catastrophe: they usually rupture in the early trimester. Very few cases of rudimentary horn pregnancies ending up in a live birth are reported. Bleeding is usually profuse from the ruptured rudimentary horn due to the thick wall with vascularity and results in acute pain with hemoperitoneum [2,3]. Pregnancy in a rudimentary horn with viable fetus and the neonatal survival has been reported as about 10 %, and 2% respectively [2]. Diagnosis of rudimentary horn pregnancy is quite taxing while clinical judgement and Ultrasonography (USG) are useful guides, Magnetic resonance imaging (MRI) is diagnostic. Associated placenta accreta in such condition further adds to the morbidity. Associated placenta accreta in such condition further adds to the morbidity. Only ten cases of such an association have been reported in the past approximately.

We are presenting a rare case of rudimentary horn pregnancy with placenta percreta in a non communicating horn of unicornuate uterus, which was initially diagnosed as abdominal pregnancy. Timely diagnosis and laparotomy resulted in an optimal maternal-fetal outcome.

Case report:

A 30 year old multigravida was referred to the obstetric emergency unit with suspected abdominal pregnancy at around 34 weeks period of gestation (POG). She was fourth gravida with previous three full term vaginal deliveries. There was no history suggestive of previous preterm delivery, ectopic pregnancy or laparotomy. Antenatal period was inadequately supervised with a single sonogram at around 23 weeks which was suggestive of a single intrauterine pregnancy

at 22 weeks. Her pregnancy was otherwise asymptomatic except for history of occasional abdominal pain for the past 2 weeks when she was advised a scan and referred thereafter. Recent sonogram was suggestive of a live abdominal pregnancy of 33 weeks with breech presentation and reduced amniotic fluid. On admission her vitals were stable and Hb was 9.7g %. Clinical findings revealed a gravid relaxed uterus of 32 weeks with fetus in breech position. Per speculum examination showed a single cervix which was confirmed on digital examination. Under USG guided vaginal examination: finger was lifting the separate uterus and no presenting fetal part was felt. Clinically, differential diagnosis of either a pregnancy in the bicornuate uterus or unicornuate uterus with rudimentary horn or abdominal pregnancy was made. Sonographic examination revealed a single fetus in breech position with scanty liquor and well defined hypoechoic ring of tissue seen circumferentially surrounding the fetus. An empty uterus was also seen separately with a well defined endometrial cavity. Continuity of uterine cavity was seen anteriorly with a cervical canal. No cervix was appreciated for the gravid uterus. Before the patient could be taken up for MRI for further confirmation of the diagnosis, she had acute abdominal pain with mild uterine contractions. She showed pallor and her peripheries were cold. Heart rate was 110 beats per minute, abdominal examination revealed a contracting uterus with well maintained contour. Simultaneously she had syncopal attack and was thus prepared for laparotomy with transfusion of one unit of whole blood. Intraoperatively it revealed a smaller non pregnant uterus with large pregnant non communicating left rudimentary horn with placenta percreta (Figure 1). Placenta was seen perforating out of the uterine serosa of rudimentary horn with approximately 1.5 liters of hemoperitoneum. Oozing of blood was seen though the serosa; however no rupture of uterine wall was noted. A classical Caesarean section was done and a live born baby girl weighing 1.5 kg was delivered with APGAR score of 3,6,9. Excision of left Rudimentary horn and left fallopian tube along with right sided tubal ligation was done. Two units of packed red blood cells were transfused in the postoperative period. Postoperative period was uneventful till her discharge on Day 8 post laparotomy. The newborn baby was doing well and discharged on D 15 of nursery stay. Histopathological examination confirmed the diagnosis of rudimentary

horn pregnancy with placenta accreta.

DISCUSSION

Pregnancy in a rudimentary horn of unicornuate uterus is a very rare occurrence (1:76,000-1:40,000) [4]. It occurs most commonly in a non communicating cavity of the unicornuate uterus. Majority of these

Sonography is pinpointing and reveals a pseudo pattern of an asymmetrical bicornuate uterus with absence of apparent continuity between cervical canal and cavity of pregnant horn. Gestational sac reveals myometrium all around. In the index case too, there was a ring of tissue seen all around the fetus with a separate empty uterus and well defined endometrial cavity. Cervix was also

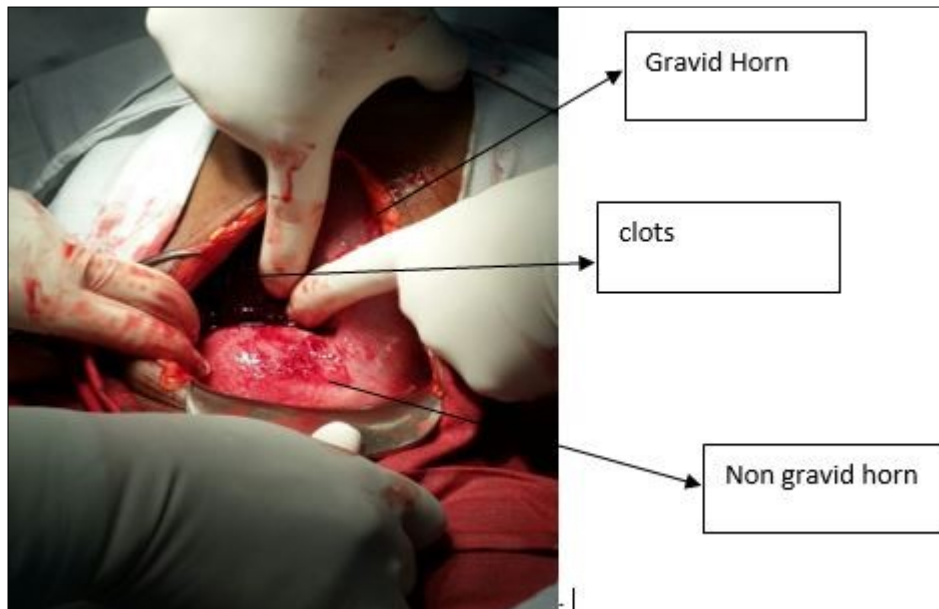


Figure 1: Intraoperative picture of the uterus with both horns and clots in peritoneal cavity

rudimentary horns are non-communicating; therefore the incidence of rupture is very high (80-90%). Pregnancy occurs in the horn through the transperitoneal migration of sperms through through contralateral tube or the trans-peritoneal migration of the fertilized ovum. There are only few case reports of such pregnancies reaching term gestation as majority of them end up in rupture of horn in early pregnancy. Clinically, such pregnancies may remain asymptomatic or may be incidentally detected with fetal malpresentations and preterm labour. Patients may also present with acute abdominal pain and may land up in shock due to uterine rupture and blood loss. There have been reported cases of such pregnancies reaching post term as well [5,6]. Goel et al have reported one such case of a live birth in an unruptured horn at 41 weeks POG [6].

Clinical examination in early pregnancy often reveals a uterus deviated to one side with a palpable adnexal mass outside uterine angle (Bart de Faille Sign) or fundus displaced to contralateral side and elevated uterine horn (Ruge Simne Syndrome).

seen in continuity with the non-gravid horn of the uterus. MRI is the gold standard noninvasive diagnostic tool at a later gestation [7] as the overall sensitivity of sonography decreases with advanced gestational age. MRI helps in the accurate evaluation of uterine connectivity to the horn. A thorough evaluation of renal and skeletal anomalies must be done concurrently. Bilateral kidneys were normal in the index case.

Apart from the morbidity and risks due to horn rupture, another added complication in such pregnancies may be due to abnormal placentation eg morbidly adherent placenta [7, 8]. The reported incidence of placenta accreta is greater than 10% in such cases [8, 9]. This occurs due to the dysfunctional endometrium of rudimentary horns leading to abnormal implantation and hemorrhagic morbidity in such cases. In the index case, the pregnancy in the non communicating horn was associated with placenta percreta and timely laparotomy helped in salvaging the baby and mother. Among all ten cases of such an association reported in the past, eight had hemorrhagic rupture while in two laparotomy was done before the rupture

[9,10]. Similar cases of presence of adherent placenta in non communicating unruptured rudimentary horn of a unicornuate uterus and delivery of a term live baby have been reported by Patra and Shrivastava et al [10,11]. Diagnosis in such cases is often difficult and clinical presentation often mimics that of abdominal pregnancy as seen in the index case [5].

Surgical modality is the gold standard of treatment with removal of gravid horn to prevent rupture and recurrence of pregnancy. Hysterectomy is warranted in severe hemorrhage [2]. Pregnancies in early trimester may be managed medically or laparoscopically.

To conclude, pregnancy in non communicating rudimentary horn with viable fetus and placenta accreta is an extremely rare entity. Increased awareness, detailed clinical evaluation, high index of suspicion for early prerupture diagnosis and timely decision of laparotomy are integral part of management in achieving optimal maternal and neonatal outcome.

Conflict of Interest: The authors declare that they have no conflict of interest to disclose

References:

1. Nahum GC. Rudimentary uterine horn pregnancy. The 20th century worldwide experience of 588 cases. *J Reprod Med.* 2002; 47:151-63
2. Goncalves E, Prata JP, Ferreira S, et al. An unexpected near term pregnancy in a rudimentary uterine horn: case report. *Case Rep Obstet Gynecol.* 2013; Article ID 307828, 4 pp.
3. Kanagal DV, Hanumanalu LC. Ruptured rudimentary horn pregnancy at 25 weeks with previous vaginal delivery: a case report. *Case Rep Obstet Gynecol.* 2012; Article ID 985076, 4 pp
4. Junqueira B, Allen L, Spitzer R, et al. Mullerian duct anomalies and mimics in children and adolescents: correlative intraoperative assessment with clinical imaging. *Radiographics* 2009;29:1085-1103
5. Feteh VF, Dimala CA, Njim T, Fuka B. Post term pregnancy in a non-communicating rudimentary horn of a unicornuate uterus. *BMC Res Notes.* 2016;9:209.
6. Goel P, Saha PK, Mehra R, Huria A: Unruptured postdated pregnancy with a live fetus in a noncommunicating rudimentary horn. *Indian J med Sci* 2007 Jan;61(1):23-7
7. Tsafrir A, Rojansky N, Sela HY, et al. Rudimentary horn pregnancy: first-trimester prerupture sonographic diagnosis and confirmation by magnetic resonance imaging. *J Ultrasound Med.* 2005;24 (2):219–23
8. Ara S, Baby R, Talib S. Unruptured term pregnancy with an alive fetus in a non communicating rudimentary horn with placenta percreta. *A.P.M.C.* 2012;6:211–3
9. Henriet E, Roman H, Zanati J, et al. Pregnant noncommunicating rudimentary uterine horn with placenta percreta. *JSLs.*2008;12:101–3.
10. Term Pregnancy with a Live Fetus in Non-communicating Rudimentary Horn with Placenta Percreta. Shrivastava N, Yadav S, Shrivastava V. *J Obstet Gynaecol India.* 2015;65:339-41.
11. Patra S, Puri M, Trivedi SS, Yadav R, Bali J. Unruptured term pregnancy with a live fetus with placenta percreta in a non-communicating rudimentary horn. *Congenit Anom (Kyoto).* 2007;47:156-7